

# Shoulder pain

## What is shoulder pain?

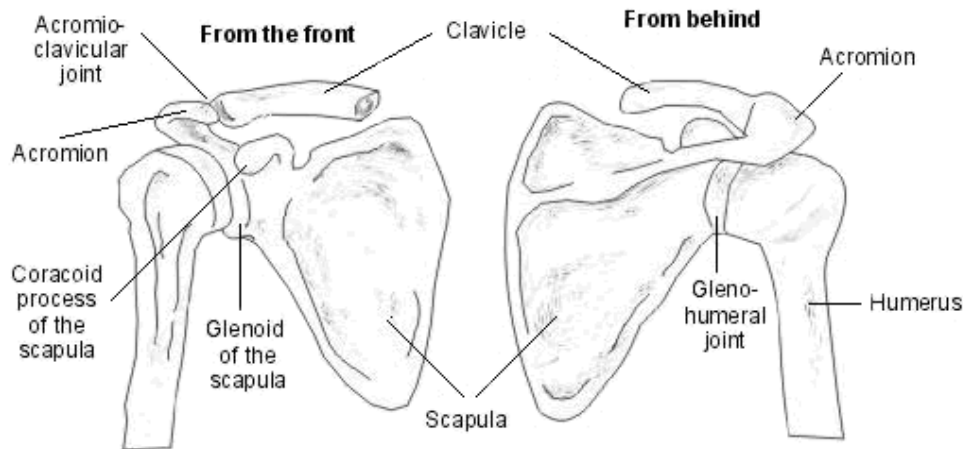
Shoulder pain is a common symptom in primary care. It can be due to an intrinsic shoulder problem like calcific tendonitis, but pain can also be referred from other structures such as the neck, diaphragm or the heart. Common shoulder problems share overlapping clinical features. When assessing shoulder pain, it is important to look for any 'red flags' that mean investigation and diagnosis need a more focused or urgent approach.

## Anatomy of the shoulder joint

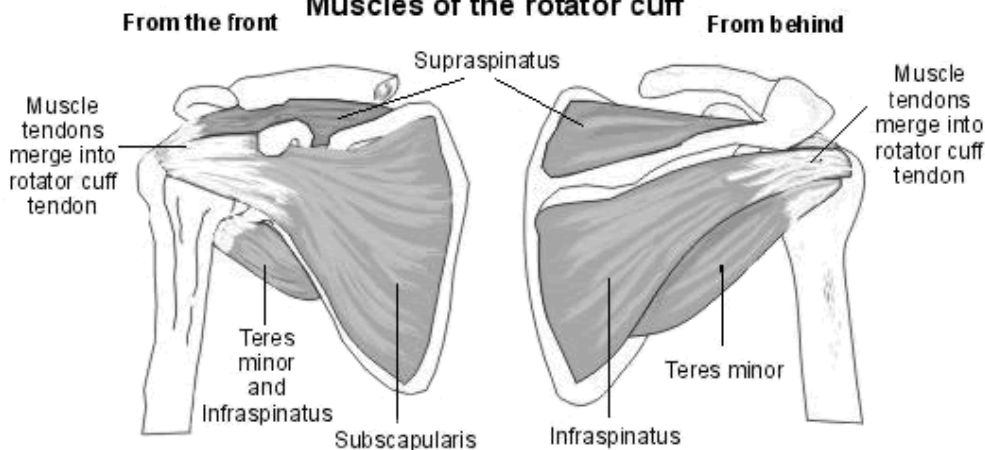
The humerus, glenoid, scapula, acromion, clavicle and surrounding soft tissues make up the shoulder. There are three significant articulations: the sternoclavicular joint, the acromioclavicular joint and the glenohumeral joint. The glenohumeral joint is the most commonly dislocated major joint in the body.

Ligaments and surrounding musculature, including the rotator cuff muscles, contribute to shoulder joint stability. The rotator cuff is composed of the four muscles: supraspinatus, infraspinatus, teres minor and subscapularis that interlock to function as one unit. These muscles help with internal and external rotation of the shoulder and importantly depress the humeral head against the glenoid as the arm is elevated. The tendons join together to form one tendon, the rotator cuff tendon. This passes through the subacromial space. The subacromial bursa, which has a large number of pain sensors, fills the space between the acromion and the rotator cuff tendon<sup>[1]</sup>.

### Bones of the shoulder (right side)



### Muscles of the rotator cuff



## Epidemiology<sup>[2]</sup>

- Shoulder pain is the third most common cause of musculoskeletal consultation in primary care.
- 1% of adults with new shoulder pain consult their GP each year.
- Self-reported prevalence of shoulder pain is between 16% and 26%.

### Risk factors for shoulder pain

- Physical factors related to occupation including repetitive movements and exposure to vibration from machine tools.
- Psychosocial factors related to work may also be risk factors for shoulder pain, including stress, job pressure, social support and job satisfaction.

- Athletes whose sports involve overhead activities, or high-impact contact sports, are prone to shoulder pain.
- Occupations particularly prone to shoulder pain syndromes include: cashiers, garment makers, bricklayers/construction workers, pneumatic tool operators, welders, meat/food-processing workers, hairdressers, plasterers, painters and decorators, assembly/production line workers, and workers using keyboards for long periods - eg, IT, secretarial.

## Shoulder pain causes<sup>[2]</sup>

Patients presenting in primary care often have a combination of different shoulder problems.

- Intrinsic shoulder pain:
  - Rotator cuff disorders:
    - Rotator cuff tears.
    - 'Subacromial pain', which may be due to impingement if the humeral head is not depressed sufficiently to slide under the acromion on elevation of the arm. It is also sometimes referred to as subacromial bursitis, tendonitis or tendinopathy.
    - Calcific tendonitis.
  - Glenohumeral disorders: [adhesive capsulitis \('frozen shoulder'\)](#), arthritis.
  - [Acromioclavicular joint problems](#).
  - [Biceps tendinopathy](#).
  - Infection (rare).
  - Shoulder instability - associated with hypermobility, including subluxation or dislocation (see also the separate article [Shoulder Dislocation](#)).

- Extrinsic shoulder pain:
  - Referred pain: [neck pain](#), myocardial ischaemia, referred diaphragmatic pain (eg, gallbladder disease, subphrenic abscess).
  - [Polymyalgia rheumatica](#).
  - Malignancy: apical lung cancers, metastases.

The four most common causes of shoulder pain and disability in primary care are rotator cuff disorders, glenohumeral disorders, acromioclavicular joint disease and referred neck pain<sup>[2]</sup> .

### **Rotator cuff disorders**

The term subacromial pain (synonyms: subacromial impingement; impingement syndrome; rotator cuff syndrome; supraspinatus tendonitis; rotator cuff tendinopathy; painful arc syndrome) refers to all rotator cuff lesions, including all stages of tendon disease from early degeneration through to complete tears.

- Most often present in patients aged 35–75 years.
- Subacromial impingement is the most common source of shoulder pain:
  - There may be a history of heavy lifting or repetitive movements, especially above shoulder level. However, it often occurs in the non-dominant arm and in non-manual workers.
  - On examination there may be muscle wasting with pain on movements and a partial restriction of active movements (passive movements are full but painful).
  - A painful arc (between 70–120° of active abduction) is not specific or sensitive but increases the likelihood of a rotator cuff disorder.

- A rotator cuff tear:
  - Usually follows trauma in young people. It is usually atraumatic in elderly people and caused by attrition from bony spurs on the undersurface of the acromion or intrinsic degeneration of the cuff, possibly.
  - Partial tears may be difficult to differentiate from rotator cuff tendinopathy on examination.
  - The drop arm test (see 'Examination', below) may be used to detect a massive tear.
- Calcific tendonitis<sup>[3]</sup> :
  - Crystalline calcium phosphate is deposited in the rotator cuff tendon.
  - The cause is not known. It is more common in women (70% of cases) and affects people aged 30–60.
  - It is a self-limiting condition as the calcium will eventually resorb but may take many years.

## Glenohumeral disorders

- [Adhesive capsulitis](#) most often presents between the ages of 40–65 years, whereas [osteoarthritis](#) is most common in those aged 60 years or older.
- Adhesive capsulitis (frozen shoulder) and arthritis often present with a history of non-adhesive capsulitis symptoms, cause deep joint pain and restrict activities such as putting on a jacket – because of impaired external rotation.
- Adhesive capsulitis is more common in people with [diabetes](#) and may also occur after prolonged immobilisation.
- There is usually generalised shoulder pain and a restriction of passive and active movements.

## Acromioclavicular disorders

See also the separate article [Acromioclavicular Joint Problems](#).

- They are usually caused by trauma or osteoarthritis.
- Pain and tenderness are localised to the acromioclavicular joint and there is a restriction of passive, horizontal movement of the arm across the body when the elbow is extended.
- Obvious deformity after injury suggests a significant tear of the acromioclavicular ligament .
- Acromioclavicular osteoarthritis may cause subacromial impingement.

## Referred neck pain

See also the separate article [Neck Pain \(Cervicalgia\) and Torticollis](#).

- Typically, this presents with pain and tenderness of the lower neck and suprascapular area, with pain referred to the shoulder and upper arm.
- There may be a restriction of shoulder movement and movement of the neck and shoulder may reproduce more generalised upper back, neck and shoulder pain.
- There may also be upper limb paraesthesia.

## Shoulder pain assessment<sup>[2]</sup>

When assessing shoulder pain, take a history and perform an examination with these questions in mind:

- Is the pain arising from the shoulder, neck or elsewhere?
- Are there any 'red flag' symptoms/signs?
- Is the pain localised to the acromioclavicular joint: the 'pointing sign'? If yes, there is acromioclavicular joint disease.
- Is there global pain and restriction of all active and passive movements? If yes, this suggests glenohumeral joint disorder (either '[frozen shoulder](#)' or arthritis).
- Does the patient show a broad area of pain: the 'grasping sign' suggestive of subacromial pain?

## History

Points to cover in the history include<sup>[2]</sup> :

- The nature of the pain including:
  - How the pain started.
  - Any specific injury.
  - Whether it is acute or chronic.
  - Any impact on function/activities of daily living.
  - Whether the pain is on the side of the dominant hand.
  - Whether there is pain at rest or on movement.
  - Whether there is night pain that affects sleep.
- Any associated pain - for example, neck, chest or other upper limb or joint pain.
- Any history of shoulder pain/instability/dislocation.
- The patient's occupation.
- The patient's sporting activities.
- Any signs or symptoms of systemic illness.
- Past medical history (particularly any history of diabetes, coronary heart disease, cancer).
- Drug history and adverse drug reactions.

### **Examination**<sup>[2]</sup> <sup>[4]</sup>

See the separate article [Shoulder Examination](#) for further information.

There are over 100 specific 'Orthopaedic Special Tests' to detect shoulder pathology but few are sensitive or specific enough to be diagnostically discriminatory<sup>[5]</sup> .

- Examine the neck, axilla and chest wall.
- Examine the cervical spine and assess range of motion.

- Inspect from the front, side, and behind for muscle wasting, swelling and deformity, or for bruising.
- Palpate the sternoclavicular, acromioclavicular and glenohumeral joints. Look for tenderness, swelling, warmth and crepitus.
- As an initial screening test, ask the person to place the palms of their hands at the base of the neck with elbows pointing laterally and then to put their arms down and try to put the back of the hands between the shoulder blades. However, be aware that this also involves joints other than the shoulder (ie elbow, wrist).
- Assess the power, stability and range of motion (active, passive and resisted) in both shoulders.
- Look for a painful arc (pain between 70-120° of abduction).
- Test passive external rotation (reduced in 'frozen shoulder'). With the elbow held into the side, turn the arm outwards as far as possible.
- Perform the 'drop arm test': passively abduct the patient's shoulder. Then ask the patient to lower the abducted arm slowly to the waist. This can identify a massive rotator cuff tear. They may be able to lower the arm slowly to 90° because this uses mostly the deltoid muscle but, below 90°, the arm will drop to the side.
- Perform the 'cross-arm test': this isolates the acromioclavicular joint. Ask the patient to raise the arm to 90° straight in front of them. Then ask the patient to adduct the arm across the chest. If there is an acromioclavicular joint problem, there will be pain in the area of the joint.

## Investigations

- Blood tests including [FBC](#), [ESR/CRP](#) and radiology such as CXR are generally only necessary if there are 'red flag' symptoms/signs <sup>[2]</sup> .
- Ultrasonography is the preferred imaging test for the shoulder.
- Plain X-rays rarely help except to confirm shoulder dislocation and shoulder arthritis <sup>[6]</sup> .
- Magnetic resonance arthrogram is useful in shoulder instability <sup>[6]</sup> .



- If referred neck pain is suspected then cervical spine X-rays may be helpful but the diagnosis is usually clinical.

## Shoulder pain treatment and management

See also the separate article [Shoulder Joint Replacements](#).

There is a lack of well-designed clinical trials in the management of shoulder disorders. Management in primary care is usually conservative: reduce or avoid overhead activities; attention to any contributing factors; medication for pain relief, including corticosteroid injection. If symptoms don't settle quickly or are severe initially, physiotherapy focused on the specific cause is indicated<sup>[7]</sup>.

- Rotator cuff disorders:
  - Advise modification of activities, including reducing precipitating movements (eg, reaching overhead).
  - Offer analgesia; paracetamol with or without codeine, or an oral non-steroidal anti-inflammatory drug (NSAID).
  - Refer to physiotherapy with the goal of optimising shoulder function, using an evidence-based rehabilitation protocol<sup>[8]</sup> .
  - Consider a subacromial corticosteroid injection if the person has limited function because of pain and is therefore unable to perform strengthening and stabilising exercises. They may be of short-term benefit when used alone<sup>[7]</sup> . See the separate [Joint Injection and Aspiration](#) article.
  - Do not give a corticosteroid injection if:
    - The person has previously received a corticosteroid injection from an experienced practitioner with minimal or no benefit.
    - The person has already had three or more injections in the same shoulder in the previous year.
    - There is a suspected significant rotator cuff tear.
    - There is any contra-indication to corticosteroid injection (eg, infection, [osteomyelitis](#)).
  - Evidence shows that physiotherapy and steroid injections may be equally helpful in the short term<sup>[9]</sup> . Injections may be repeated if the initial response is good.

- Rotator cuff tears<sup>[10]</sup> :
  - Physiotherapy and steroid injections may be helpful for minor tears.
  - Suspected large tears that are symptomatic may benefit from early referral for orthopaedic input.
  - Surgical treatment usually involves arthroscopic rotator cuff tendon repair.
- Calcific tendonitis<sup>[3]</sup> :
  - When calcific tendonitis is symptomatic, it may present as chronic, relatively mild pain in the shoulder, with sporadic episodes of severe, acute pain radiating down the arm or to the neck.
  - The calcium deposits cause a chemical irritant inflammatory reaction. There is also an increase in pressure in the tendon, which in turn leads to malfunction of the rotator cuff and subacromial pain.
  - Treatment for calcific tendonitis includes NSAIDs, corticosteroids, physiotherapy, aspiration or lavage. For patients refractory to these treatments, open or arthroscopic shoulder surgery may be offered to excise the deposit.
  - Extracorporeal shock wave lithotripsy is no longer recommended by the National Institute for Health and Care Excellence (NICE).
- Glenohumeral disorders: see the separate article [Adhesive Capsulitis of the Shoulder](#).
  - Glucocorticoid injection appears to be more effective in the short term than physiotherapy and exercises<sup>[11]</sup> .

- Acromioclavicular disease (see the separate [Acromioclavicular Joint Problems article](#)):
  - Acromioclavicular injury usually responds to rest and simple analgesia, unless there is significant disruption of the joint, in which case orthopaedic referral is necessary<sup>[12]</sup> .
  - Consider providing a sling for 5–7 days if an acromioclavicular joint injury is suspected.
  - Consider referring to physiotherapy after 4–6 weeks if the person responds poorly to rest and analgesia.
- Degeneration of the humeral head<sup>[13]</sup> :
  - The humeral head may degenerate as a result of a range of conditions – eg, osteoarthritis, [rheumatoid arthritis](#) or avascular necrosis. The whole or only part of the articular surface of the humeral head may be affected.
  - Conservative treatment includes physiotherapy, pain relief, topical or oral NSAIDs and corticosteroid injections.
  - Patients who do not respond to conservative treatments may need surgery, which involves either shoulder arthroplasty using a stemmed humeral head prosthesis, or fusion of the joint.
  - Shoulder resurfacing arthroplasty replaces only the damaged joint surfaces, with minimal bone resection and is recommended by NICE as a surgical option.
- Muscle strains:
  - Muscle strains of the shoulder are very common, including trapezius and rhomboid strains.
  - Treatment of muscle strains includes rest, ice/heat, compression and elevation (sitting up) as well as massage, non-steroidal anti-inflammatory drugs (topical or oral) and further analgesia as required.
  - Severe or persistent strains may require physiotherapy.

There is no good-quality evidence to say whether acupuncture works to treat shoulder pain of any cause or if it is harmful<sup>[14]</sup> .

# Criteria for referral to secondary care<sup>[4]</sup>

Emergency same day assessment if:

- Suspected joint infection (red skin, fever or systemically unwell).
- Unreduced dislocation (trauma, epileptic fit or electric shock leading to abnormal shoulder shape and loss of rotation).
- Acute trauma, depending on clinical judgement.

Urgent if any red flags are identified:

- Trauma, pain and weakness, or sudden loss of ability to actively raise the arm (with or without trauma): suspect acute rotator cuff tear.
- Any shoulder mass or swelling: suspect malignancy.
- Red skin, painful joint, fever or the person is systemically unwell: suspect septic arthritis.
- Trauma leading to loss of rotation and abnormal shape: possible shoulder dislocation.
- New symptoms of inflammation in several joints: suspect inflammatory arthritis.

Consider urgent investigations and/or referral to secondary care if:

- Systemic symptoms – eg, fever, night sweats, weight loss or new respiratory symptoms.
- Undiagnosed severe shoulder pain or severe restriction of movement.
- History of trauma and the person is seen acutely.

Urgent referral for suspected:

- Malignancy (past history of cancer, symptoms or signs of cancer, mass or swelling, unexplained deformity, lymphadenopathy). Follow the two-week referral pathway.
- Acute rotator cuff tear caused by trauma (trauma, pain and weakness).

- Inflammatory arthritis.
- Neurological lesion (unexplained wasting, significant motor or sensory deficit). Discuss with neurology, neurosurgery or orthopaedics.

Refer early to secondary care if:

- Recurrent shoulder instability.
- Severe post-traumatic pain.
- Pain is having a significant impact – eg, work or sport activities.

Refer if pain and function are not improving following conservative treatment for three months.

Consider referral to a specialised musculoskeletal clinic – for example, for provision of physiotherapy or corticosteroid injection.

## Shoulder pain prognosis<sup>[7]</sup>

- The prognosis of chronic shoulder pain depends on the underlying cause.
- Increasing age, female sex, symptoms of gradual onset, prolonged symptoms, severe or recurrent symptoms and associated neck pain are associated with a worse outcome<sup>[2]</sup>.
- Recovery in shoulder pain is generally slow. Studies have shown complete recovery at one month in 23% of patients and at 18 months in 59% of patients.

---

## Further reading

- [Shoulder Disorders](#); Wheeless' Textbook of Orthopaedics

**Disclaimer:** This article is for information only and should not be used for the diagnosis or treatment of medical conditions. Egton Medical Information Systems Limited has used all reasonable care in compiling the information but makes no warranty as to its accuracy. Consult a doctor or other healthcare professional for diagnosis and treatment of medical conditions. For details see our [conditions](#).

Authored by:	Peer Reviewed by: Dr Laurence Knott	
Originally Published: 20/11/2023	Next review date: 18/10/2021	Document ID: doc_2777

---

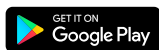View this article online at: [patient.info/doctor/shoulder-pain-pro](https://patient.info/doctor/shoulder-pain-pro)

Discuss Shoulder pain and find more trusted resources at [Patient](https://patient.info).

---



To find out more visit [www.patientaccess.com](https://www.patientaccess.com)  
or download the app



Follow us

