

## Chest X-ray – systematic approach

Reading a chest X-ray (CXR) requires a systematic approach. It is tempting to leap to the obvious but failure to be systematic can lead to missing 'barn door' pathology, overlooking more subtle lesions, drawing false conclusions based on a film that is technically poor and, hence, misleading, or even basing management on an inaccurate interpretation. There is not just one way to examine a CXR but every doctor should develop their own technique. This article is not a *tablet of stone* but should be a good starting point to develop one's own routine.

Traditionally, GPs rarely see X-rays but CXRs remain an important diagnostic tool for GPs and appear to be a cost-effective diagnostic test<sup>[1]</sup>. Hence, learning to interpret X-rays is a skill learned as a junior hospital doctor that should not be lost. There may be occasions when a GP has to make decisions based on an unreported film.

### The 'right film for the right patient'

This may sound pedantic but it is very important<sup>[2]</sup>. Check that the film bears the patient's name. However, as names can be shared, check other features such as date of birth or hospital number too. The label may also tell of unusual but important features such as anteroposterior (AP) projection or supine position.

Having checked that it is the correct patient, check the date of the film to ascertain which one you are viewing.

### Technical details

Technical aspects should be considered briefly:

- Check the position of the **side marker** (left or right) against features such as the apex of the heart and air bubble in the stomach. A misplaced marker is more common than dextrocardia or situs inversus.

- Most films are a posteroanterior (PA) **projection**. The usual indication for AP is a patient who is confined to bed. It may be noted on the radiograph. If there is doubt, look at the relationship of the scapulae to the lung margins. A PA view shows the scapulae clear of the lungs whilst in AP projection they always overlap. Vertebral endplates are more clearly visible in AP and laminae in PA. This is important because the heart looks bigger on an AP view. The distance from the tube to the patient is also usually reduced in portable films and this also enlarges the shadow of the heart. X-rays are not so much like pictures as like shadows.
- The normal **posture** for films is erect. Supine is usually for patients confined to bed. It should be clear from the label. In an erect film, the gastric air bubble is clearly in the fundus with a clear fluid level but, if supine, in the antrum. In a supine film, blood will flow more to the apices of the lungs than when erect. Failure to appreciate this will lead to a misdiagnosis of pulmonary congestion.
- **Rotation** should be minimal. It can be assessed by comparing the medial ends of the clavicles to the margins of the vertebral body at the same level. Oblique chest films are requested to look for achalasia of the cardia or fractured ribs.
- CXR should be taken with the patient in full **inspiration** but some people have difficulty holding full inspiration. The major exception is when seeking a small pneumothorax as this will show best on full expiration. A CXR in full inspiration should have the diaphragm at the level of the 6th rib anteriorly and the liver pushes it up a little higher in the right than on the left. Do not be unduly concerned about the exact degree of inflation.
- **Penetration** is affected by both the duration of exposure and the power of the beam. More kV gives a more penetrating beam. A poorly penetrated film looks diffusely light (an X-ray is a negative) and soft tissue structures are readily obscured, especially those behind the heart. An over-penetrated film looks diffusely dark and features such as lung markings are poorly seen.
- Note **breast shadows** in adult women.

So far you have checked that it is the right film for the right patient and that it is technically adequate.

# Systematic search for pathology

Just as palpation of the abdomen and auscultation of the heart are the last parts of that examination, so must the search for pathology be deferred until the preliminaries have been completed<sup>[3]</sup>.

- Have a brief look for obvious unusual opacities such a chest drain, a pacemaker or a foreign body. This is a two-dimensional picture and so a central opacity may not be something that was swallowed and is now impacted in the oesophagus. It might be a metal clip from a bra strap or a hair band on a plait.
- Look at the mediastinal contours, first to the left and then to the right. The trachea should be central. The aortic arch is the first structure on the left, followed by the left pulmonary artery. The branches of the pulmonary artery fan out through the lung.
- Check the cardio-thoracic ratio (CTR). The width of the heart should be no more than half the width of the chest. About a third of the heart should be to the right and two thirds to the left of centre. **NB:** the heart looks larger on an AP film and thus you cannot comment on the presence or absence of cardiomegaly on an AP film.
- The left border of the heart consists of the left atrium above the left ventricle. The right border is only the right atrium alone and above it is the border of the superior vena cava. The right ventricle is anterior and so does not have a border on the PA CXR film. It may be visible on a lateral view.
- The pulmonary arteries and main bronchi arise at the left and right hila. Enlarged lymph nodes or primary tumours make the hilum seem bulky. Know what is normal. Abnormality may be caused by lung cancer or enlarged nodes from causes including sarcoidosis (bilateral hilar lymphadenopathy) and lymphoma.
- Now look at the lungs. The pulmonary arteries and veins are lighter and air is black, as it is radiolucent. Check both lungs, starting at the apices and working down, comparing left with right at the same level. The lungs extend behind the heart, so try to look there too. Note the periphery of the lungs - there should be few lung markings here. Disease of the air spaces or interstitium increases opacity. Look for a pneumothorax which shows as a sharp line of the edge of the lung.

- Ascertain that the surface of the hemidiaphragms curves downwards and that the costophrenic and cardiophrenic angles are not blunted. Blunting suggests an effusion. Extensive effusion or collapse causes an upward curve. Check for free air under the hemidiaphragm - this occurs with perforation of the bowel but also after laparotomy or laparoscopy.
- Finally look at the soft tissues and bones. Are both breast shadows present? Is there a fractured rib? If so, check again for a pneumothorax. Are the bones destroyed or sclerotic?

There are some areas where it is very easy to miss pathology and so it is worth repeating examination. Attention may be merited to apices, periphery of the lungs, under and behind the hemidiaphragms and behind the heart. The diaphragm slopes backwards and so some lung tissue is below the level of the highest part of the diaphragm on the film.

## Lateral films<sup>[4]</sup>

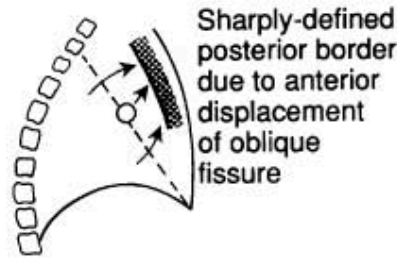
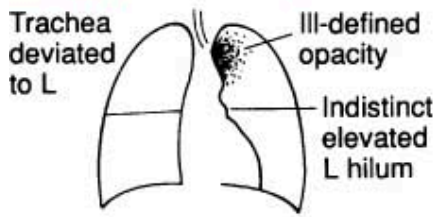
A lateral view may have been requested or performed on the initiative of the radiographer or radiologist. As an X-ray is a two-dimensional shadow, a lateral film helps to identify a lesion in three dimensions. The usual indication is to confirm a lesion seen on a PA film.

The heart lies in the antero-inferior field. Look at the area anterior and superior to the heart; this should be black because it contains aerated lung. Similarly, the area posterior to the heart should be black right down to the hemidiaphragms. The degree of blackness in these two areas should be similar, so compare one with the other. If the area anterior and superior to the heart is opacified, it suggests disease in the anterior mediastinum or upper lobes. If the area posterior to the heart is opacified there is probably collapse or consolidation in the lower lobes.

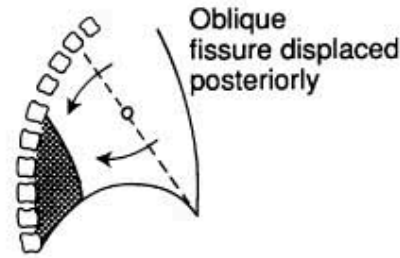
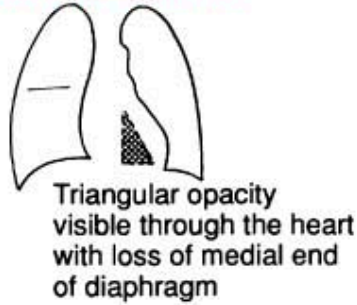
## Diagrams

The following diagrams help to understand the interpretation of the CXR.

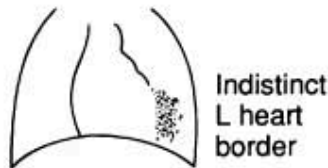
**Left upper-lobe collapse**



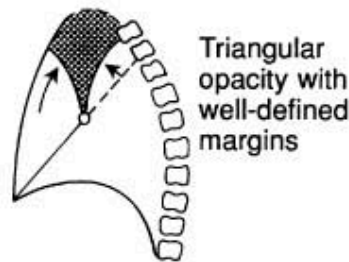
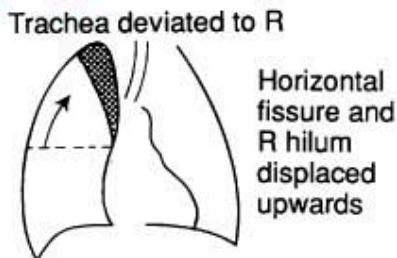
**Left lower-lobe collapse**



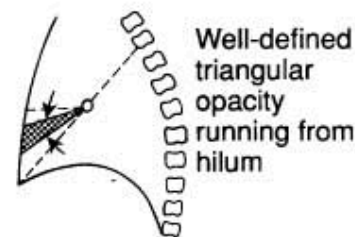
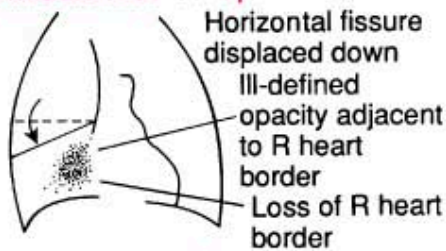
**Lingular consolidation**



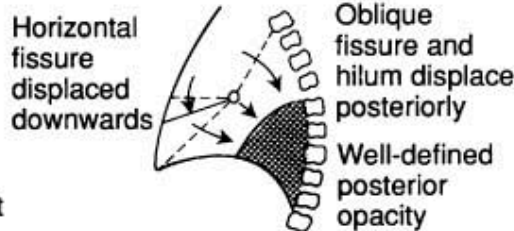
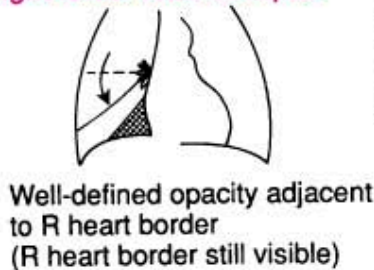
**Right upper lobe collapse**



**Right middle lobe collapse**



**Right lower-lobe collapse**



**Abnormal opacities**

When observing an abnormal opacity, note:

- Size and shape.
- Number and location.
- Clarity of structures and their margins.
- Homogeneity.

If available, compare with an earlier film.

The common patterns of opacity are:

### **Collapse and consolidation**

Collapse - also called atelectasis - and consolidation are caused by the presence of fluid instead of air in areas of the lung. In an air bronchogram the airway is highlighted against denser consolidation and vascular patterns become obscured.

- Confluent opacification of the hemithorax may be caused by consolidation, pleural effusion, complete lobar collapse and after a pneumonectomy. Consolidation is usually interpreted as meaning infection but it is impossible to differentiate between infection and infarction on X-ray. The diagnosis of pulmonary embolism requires a high index of suspicion.
- To find consolidation, look for absence or blurring of the border of the heart or hemidiaphragm. The lung volume of the affected segment is usually unaffected.
- Collapse of a lobe (atelectasis) may be difficult to see. Look for a shift of the fissures, crowding of vessels and airways and possible shadowing caused by a proximal obstruction like a foreign body or carcinoma.
- A small pleural effusion will cause blunting of the costophrenic or cardiophrenic angles. A larger one will produce an angle that is concave upwards. A very large one will displace the heart and mediastinum away from it, whilst collapse draws those structures towards it. Collapse may also raise the hemidiaphragm.

### **Heart and mediastinum**

- The heart and mediastinum are deviated **away** from a pleural effusion or a pneumothorax, especially if it is a tension pneumothorax and **towards** collapse.
- If the heart is enlarged, look for signs of heart failure with an unusually marked vascular pattern in the upper lobes, wide pulmonary veins and possible Kerley B lines. These are tiny horizontal lines from the pleural edge and are typical of fluid overload with fluid collecting in the interstitial space.
- If the hilum is enlarged, look for structures at the hilum such as pulmonary artery, main bronchus and enlarged lymph nodes.

## Chest X-ray in children<sup>[5]</sup>

Children are not just small adults and this is important when interpreting a child's X-ray. Such matters as identification of the patient are still important. A child, especially if small, is more likely to be unable to comply with instructions such as keeping still, not rotating and holding deep inspiration. Technical considerations such as rotation and under- or over-penetration of the film still merit attention and they are more likely to be unsatisfactory. A child is more likely to be laid down and have an AP film with the radiographer trying to catch the picture at full inspiration. This is even more difficult with tachypnoea<sup>[6]</sup>.

### Assess lung volume

Count down the anterior rib ends to the one that meets the middle of the hemidiaphragm. A good inspiratory film should have the anterior end of the 5th or 6th rib meeting the middle of the diaphragm. More than six anterior ribs shows hyperinflation. Fewer than five indicates an expiratory film or under-inflation.

Tachypnoea in infants causes trapping of air. Expiration compresses the airways, increasing resistance and, especially under 18 months, air enters more easily than it leaves and is trapped, causing hyperinflation. Bronchiolitis, heart failure and fluid overload are all causes.

With under-inflation, the 3rd or 4th anterior rib crosses the diaphragm. This makes normal lungs appear opaque and a normal heart appears enlarged.

### Positioning

Sick children, especially if small, may not be cooperative with being positioned. Check if the anterior ends of the ribs are equal distances from the spine. Rotation to the right makes the heart appear central and rotation to the left makes the heart look large and can make the right heart border disappear.

### **Lung density**

Divide the lungs into upper, middle and lower zones and compare the two sides. Infection can cause consolidation, as in an adult. Collapse implies loss of volume and has various causes. The lung is dense because the air has been lost. In children, the cause is usually in the airway, such as an intraluminal foreign body or a mucous plug. Complete obstruction of the airway results in reabsorption of air in the affected lobe or segment. Collapse can also be due to extrinsic compression such as a mediastinal mass or a pneumothorax.

Differentiating between collapse and consolidation can be difficult or impossible, as both are denser. Collapse may pull across the mediastinum and deviate the trachea. This is important, as pneumonia is treated with antibiotics but collapse may require bronchoscopy to find and remove an obstruction.

### **Pleural effusion**

The features of effusion have already been noted for adults. In children, unilateral effusion usually indicates infection whilst bilateral effusion occurs with hypoalbuminaemia as in nephrotic syndrome.

Bronchial wall thickening is a common finding on children's X-rays. Look for 'tram track' parallel lines around the hila. The usual causes are viral infection or asthma but this is a common finding with cystic fibrosis.

### **Heart and mediastinum**

The anterior mediastinum, in front of the heart, contains the thymus gland. It appears largest at about 2 years of age but it continues to grow into adolescence. It grows less fast than the rest of the body and so becomes relatively smaller. The right lobe of the lung can rest on the horizontal fissure, which is often called the sail sign.



Assessment of the heart includes assessment of size, shape, position and pulmonary circulation. The cardiothoracic ratio is usually about 50% but can be more in the first year of life and a large thymus can make assessment difficult, as will a film in poor inspiration. As with adults, one third should be to the left of centre and two thirds to the right. Assessment of pulmonary circulation can be important in congenital heart disease but can be very difficult in practice.

---

## Further reading

- [Candemir S, Antani S](#); A review on lung boundary detection in chest X-rays. *Int J Comput Assist Radiol Surg.* 2019 Apr;14(4):563-576. doi: 10.1007/s11548-019-01917-1. Epub 2019 Feb 7.
- [Bouck Z, Mecredy G, Ivers NM, et al](#); Routine use of chest x-ray for low-risk patients undergoing a periodic health examination: a retrospective cohort study. *CMAJ Open.* 2018 Aug 13;6(3):E322-E329. doi: 10.9778/cmajo.20170138. Print 2018 Jul-Sep.

**Disclaimer:** This article is for information only and should not be used for the diagnosis or treatment of medical conditions. Egton Medical Information Systems Limited has used all reasonable care in compiling the information but makes no warranty as to its accuracy. Consult a doctor or other healthcare professional for diagnosis and treatment of medical conditions. For details see our [conditions](#).

|                                     |   |                          |
|-------------------------------------|---|--------------------------|
| Authored by:                        | Peer Reviewed by:<br>Dr Hayley Willacy, FRCGP |                          |
| Originally Published:<br>20/11/2023 | Next review date:<br>24/08/2020               | Document ID:<br>doc_1934 |

---

View this article online at: [patient.info/doctor/chest-x-ray-systematic-approach](https://patient.info/doctor/chest-x-ray-systematic-approach)

Discuss Chest X-ray – systematic approach and find more trusted resources at [Patient](#).



To find out more visit [www.patientaccess.com](http://www.patientaccess.com)  
or download the app



Follow us

