

Purpuric rashes

What is a purpuric rash?

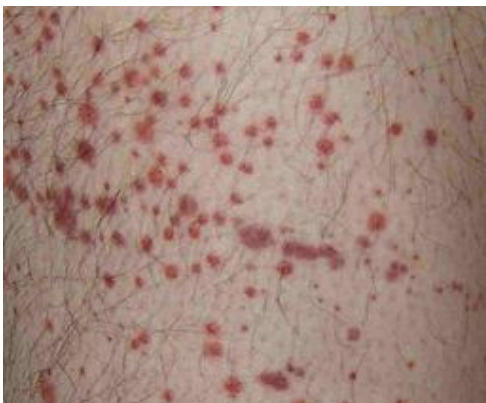
The term 'purpura' describes a purplish discolouration of the skin that is produced by small bleeding vessels near the surface. Purpura may also occur in the mucous membranes, especially of the mouth and in the internal organs. Purpura is not a disease *per se* but is indicative of an underlying cause of bleeding.

When purpura spots are very small (<1 cm in diameter), they are called petechiae or petechial haemorrhages. Larger, deeper purpura are referred to as ecchymoses or bruising.

Purpura may occur with either normal platelet counts (non-thrombocytopenic purpuras) or decreased platelet counts (thrombocytopenic purpuras). Platelets help maintain the integrity of the capillary lining as well as being important in the clotting process. As a general rule, purpura indicates a problem of the platelet system whilst a deficiency of clotting factors will cause haematomas or haemarthrosis as in haemophilia. Nevertheless, clotting factor deficiency must be considered.

Purpuric rash symptoms^[1] ^[2] ^[3]

The appearance of purpura is quite characteristic and it does not blanch on pressure.



Examination

It may seem unusual to place examination before history but there is some logic to this. In reality, the patient is likely to start the consultation by presenting with the purpuric rash and so inspection of the rash and noting such matters as the general condition of the patient will occur at the outset.

- Note the nature of the lesions – size, confluence, associated blisters (and what these contain: exudate, blood, pus).
- Note where the lesions are situated. For example, localised lesions may be caused by trauma whereas purpura due to venous hypertension will be in the lower legs with a distribution as shown below.
- Don't forget to ask/look for lesions in the mucous membranes.
- Tenderness may suggest an inflammatory process.

History

- Note the age of the patient. Henoch–Schönlein purpura tends to occur in children^[4]. Senile purpura is confined to the elderly^[5]. Leukaemia and myeloproliferative disorders can occur at any age.
- Determine how long the rash has been present and whether it is changing noticeably. Meningococcal septicaemia will be very recent in origin and changing almost visibly.
- Establish whether the patient is otherwise well. If a child has developed a purpuric, possibly meningococcal, rash but does not seem unwell, do not be lured into a false sense of security. That child may be moribund just 20 minutes later.
- Note whether general easy bruising has been noticed.
- Recent travel history should be reviewed.

Other components of a routine history should be gone through (past medical history, medical and allergic history – including any over-the-counter drugs – and social history are all relevant).

Review

Having inspected the skin and taken a history, it may be useful to return to a physical examination to reassess the purpuric rash and carry out a further systemic examination, looking for hepatomegaly/splenomegaly or neurological signs, for example. Be guided by your findings so far.

Differential diagnosis^[1]

Purpura is a sign rather than a diagnosis and a cause must be sought. It is helpful to classify causes into vascular (non-thrombocytopenic) and thrombocytopenic disorders.

Non-thrombocytopenic purpura

Causes include:

- Congenital causes such as:
 - Hereditary haemorrhagic telangiectasia ([Osler-Weber-Rendu syndrome](#)).
 - Connective tissue diseases such as [Ehlers-Danlos syndrome](#) and [pseudoxanthoma elasticum](#).
 - [Congenital cytomegalovirus \(CMV\)](#) and [congenital rubella](#).
- Acquired causes such as severe infections (eg, [septicaemia](#), [meningococcal infections](#), [measles](#)).
- Allergic causes such as Henoch-Schönlein purpura, connective tissue disorders (eg, [systemic lupus erythematosus \(SLE\)](#), [rheumatoid arthritis](#)).
- [Drug-induced causes](#) such as steroids and sulfonamides^[6] .
- Other causes, such as senile purpura, trauma, scurvy, dependent purpura with venous hypertension and factitial purpura.

Thrombocytopenic purpura

Causes include:

- Impaired platelet production such as:
 - Generalised bone marrow failure (eg, leukaemia, [aplastic anaemia](#), [myeloma](#), marrow infiltration by solid tumours).
 - Selective reduction in megakaryocytes (eg, drugs such as co-trimoxazole, chemicals, viral infections).
- Excessive platelet destruction such as:
 - Immune problems (eg, [immune thrombocytopenia](#), secondary immune thrombocytopenia - SLE, viral infections, drugs - post-transfusion purpura)^[7] .
 - Coagulation problems (eg, disseminated intravascular coagulation (DIC), immune thrombocytopenia, [haemolytic uraemic syndrome](#)).
 - Sequestration of the platelets as occurs in [splenomegaly](#).
 - Dilutional loss as might be seen following massive transfusion of stored blood.

These lists are far from exhaustive (see 'Diseases associated with a purpuric rash', below) but account for the more common causes.

Purpuric lesions can appear in normal patients, usually women. Bruises, either single or multiple, appear spontaneously, mainly on arms or legs, and resolve without any specific treatment. Senile purpura is usually seen on areas exposed to mild repeated trauma, such as the back of hands. Lesions keep their dark colour often for several weeks and there is no abnormality in bleeding times.

Investigations^[1]

This will be guided by the differential diagnosis, much of which will already have been excluded.

- FBC, ESR, platelets. The platelet count is fundamental. Leukaemia or related diseases may produce anaemia and leukocytopenia. ESR may indicate an inflammatory process. It is very nonspecific.

- LFTs to check for liver disease.
- A coagulation screen will screen for clotting factor deficiencies.
- If the patient is on warfarin, check INR.
- Plasma electrophoresis may show hypergammaglobulinaemia, paraproteinaemia and cryoglobulinaemia.
- Autoantibody screen for connective tissue disorders.

The clinical condition may indicate further investigations, including blood culture and lumbar puncture.

Diseases associated with purpuric rashes

These have been outlined in 'Differential diagnosis', above. Here are some points you may wish to bear in mind.

Bacterial infections

Those that cause purpuric rashes include meningococcal septicaemia, streptococcal septicaemia and diphtheria. Several acute viral infections also cause purpuric rashes. These include smallpox, chickenpox, measles, parvovirus B19 and haemorrhagic fevers caused by Ebola virus, Rift Valley virus and Lassa fever.

Allergic vasculitic purpura^[8]

This is caused by inflammation and infiltration of the blood vessel wall as an anaphylactic reaction to a number of physical and chemical stimuli, including infections. [Henoch-Schönlein purpura \(HSP\)](#) is one of the most common. It is often preceded by an upper respiratory tract infection due to beta-haemolytic streptococcal infection. It can occur in epidemics in young children with a fever followed by a purpuric rash which may be slightly raised. Typically, it affects the fronts of the legs and the buttocks. There may be associated acute arthritis, gastrointestinal pain and nephritis with proteinuria. The purpuric rash may continue to form over several weeks. Serious acute complications include central nervous system (CNS) bleeding, acute intussusception or acute kidney injury. Usually it is a self-limiting condition but it may respond to steroids. A Cochrane review found no evidence of benefit of short courses of prednisolone in preventing serious kidney disease in HSP^[9].

Disseminated intravascular coagulation (DIC)

With DIC there is massive ecchymosis with sharp, irregular borders of deep purple colour and an erythematous halo. It can evolve to haemorrhagic bullae and blue-black gangrene. These appear as multiple lesions, often symmetrically involving distal extremities, areas of pressure and lips, ears, nose and trunk.

Strong steroids

Long-term use of strong steroids can cause widespread purpura and bruising, normally on extensor surfaces of the hands, arms and thighs. It is caused by atrophy of the collagen fibres supporting blood vessels in the skin. A similar appearance is also found in senile-type purpura.

Blood transfusions

Severe thrombocytopenia 5-12 days after receiving a blood product containing platelets is a rare complication, usually confined to multiparous women^[10]. It is due to the production of an antibody to a specific platelet antigen that the woman normally lacks. The patient normally recovers within 1-3 weeks but the condition can be lethal and may need treatment with plasmapheresis or intravenous (IV) immunoglobulins.

Pigmented purpuric dermatoses

Pigmented purpuric dermatoses are a group of diseases characterised by erythrocyte extravasation - particularly in the lower limbs, associated with haemosiderin deposition. Think of these in chronic cases.

Amyloid^[11]

Both primary and secondary amyloid can cause purpura that is known as 'pinch purpura' because of the typical appearance on the cheeks.

Factitial purpura^[12]

This may be considered where there are episodes of inexplicable bleeding/bruising. They may represent severe emotional or psychiatric disturbance. They may also be a sign of abuse.

Purpura treatment and management

- As purpura is a physical finding rather than a disease, the management is to make a diagnosis and to act accordingly. The management of the various diseases is found in the respective articles.
- Purpura can indicate a platelet count below $30 \times 10^9/L$ and a serious haemorrhagic potential. A count of $20 \times 10^9/L$ or less requires urgent treatment.
- If a child has bruising, check all over, including the anogenital area. Keep non-accidental injury and your safeguarding responsibilities in mind.
- Never give an intramuscular (IM) injection if a serious bleeding disorder is suspected, or a very painful haematoma will develop.
- The glass test (diascope) is well known to patients and is very useful.

Disclaimer: This article is for information only and should not be used for the diagnosis or treatment of medical conditions. Egton Medical Information Systems Limited has used all reasonable care in compiling the information but makes no warranty as to its accuracy. Consult a doctor or other healthcare professional for diagnosis and treatment of medical conditions. For details see our [conditions](#).

Last updated by: Dr Laurence Knott 14/12/2021	
Peer reviewed by: Dr Hayley Willacy, FRCGP 14/12/2021	Next review date: 03/11/2026

View this article online at: patient.info/doctor/purpuric-rashes

Discuss Purpuric rashes and find more trusted resources at [Patient](#).



To find out more visit www.patientaccess.com
or download the app



Follow us

